

# Imaging of dental implants

Busnur Shilpa Jayadevappa,\* Kodhandarama GS,†  
Santosh SV ‡ and Wani Tahir Rashid S§

\* Assistant Professor, †Professor & Head, §Intern, Department of Oral Medicine and Radiology, S.J.M. Dental college and Hospital, Chitradurga - 577501, Karnataka, India.

‡Assistant Professor, Department of Psychiatry, Basaweshwara Medical college and Hospital, Chitradurga - 577501, Karnataka. India.

---

### Abstract

Dental implants are gaining immense popularity and wide acceptance because they not only replace lost teeth, but are also permanent restorations that do not interfere with oral function or speech or compromise the self-esteem of patients. Appropriate replacement planning in which imaging plays a pivotal role helps to ensure a satisfactory outcome. The development of precise presurgical imaging techniques and surgical templates allow the dentist to place these implants with relative ease & predictability. This article focuses on various types of imaging modalities carried out before, during and after dental implant placement and the diagnostic role of each modality.

**Key words:** Implants; Radiograph; Implant imaging.

### Introduction

The success of any surgical implant procedure is dependent on the careful selection and preparation of the patient (1). Imaging is the integral part of preoperative Implant assessment because it is one of the most accurate means by which the clinician can assess the morphologic features of the proposed fixture sites (2). Several imaging techniques are currently available for the presurgical and postsurgical examinations. These include both intra oral and extra oral plain film and digital radiography. A combination of techniques is usually used to obtain the necessary diagnostic information (1).

---

\*Author for correspondence: Dr. Shilpa BJ, Assistant Professor, Department of Oral Medicine and Radiology, SJM Dental College and Hospital, Chitradurga.

Karnataka. India

Tel: +91-9844821215

E-mail: shuhi44@yahoo.co.in

---



## Dental implant imaging

### Purpose of radiography

The purpose of imaging the implant site is to decide whether implant treatment is appropriate for the patient, to know the location of vital anatomical structures such as the inferior alveolar nerve and the extension of maxillary sinus, for the assessment of bone quantity, such as the height of alveolar process, the bucco-lingual width, angulation, and the detection of possible undercuts and concavities, to identify any possible pathological conditions, to estimate the length and width of the implant to be inserted, the appropriate number of implants, the location and orientation, and the possible need for additional treatment before implant placement, for instance bone augmentation procedures and to estimate the prognosis (3-7).

### Imaging objectives

The decision of when to image along with which imaging modality to use depends on the three phases (8).

1. *Preprosthetic implant imaging (Phase 1):* The objectives of this phase are to determine the quantity, quality, and angulation of bone; the relationship of critical structures to the prospective implant sites; and the presence or absence of disease at the proposed surgery sites.
2. *Surgical and Interventional implant imaging (Phase 2):* The objectives of this phase are to evaluate the surgery sites during and immediately after surgery, assist in the optimal position and orientation of dental implants, evaluate the healing and integration phase of implant surgery, and ensure abutment position and prosthesis fabrication are correct.
3. *Post prosthetic implant imaging (Phase 3):* It commences just after the prosthesis placement and continues as long as implant remains in the jaws.

The objectives of this phase are to evaluate the long-term maintenance of implant rigid fixation and function, including the crestal bone levels around each implant, and to evaluate the implant complex.

### Basic radiographic principles

1. Adequate number and type of images to provide the needed anatomic information.
2. The type of imaging technique selected should be able to provide the required information with adequate precision and dimensional accuracy.
3. There must be a way of relating the images to patient's anatomy. For edentulous regions of jaw, this generally means the use of a stent with radiopaque markers during imaging.
4. All images should be of adequate density and contrast with minimal distortion and should be free from artifacts.
5. Imaging information should be balanced with the radiation dose and cost to the patient. The ALARA (as low as reasonably achievable) principle should govern the selection of suitable technique (9).

### Ideal imaging modality characteristics

According to Pharoah MJ 1993

1. Cross-sectional views for the visualization of the spatial relationship of internal structures, such as the inferior alveolar canal, and as a means of obtaining accurate dimensions in both the vertical and the horizontal planes.
2. Minimal image distortion to permit accurate measurements.
3. Depiction of the density of the cancellous bone and thickness of the cortical plates of bone. This is of value if initial stabilization of the implant is required.

## Dental implant imaging

4. Spatial relationship of the cross-sectional views of the mandible and maxillae to one another.
5. A simple means of identifying the exact location of each cross-sectional image to the implant site that can be provided at the time of surgical placement.
6. Ready availability and reasonable cost.
7. Patient radiation dose should be small as possible (10).

The commonly used radiographic procedures with time intervals for treatment planning and assessment of dental implants are as shown in the **Table 1 (11)**.

**Table 1:** Commonly Used Radiographic Procedures with Time Intervals for Treatment Planning and Assessment of Dental Implants [11].

Stage of treatment	Time (months)	Radiographic procedures
Treatment Planning	-1	PA, Pan, tomo, CT, ceph
Surgery (Placement)	0	PA, Pan, tomo, CT, ceph for correction of problems
Healing	0 to 3	PA, Pan, tomo, CT, ceph for correction of problems
Remodeling	4 to 12	PA, Pan
Maintenance (without problems)	13+	PA, Pan, (follow up approximately every 3 years)
Complications	Anytime	PA, Pan, CT (as indicated)

*PA-Periapical; Pan-panoramic radiography; Tomo-conventional tomography; CT-reformatted computed tomography; Ceph-lateral or lateral-oblique cephalometric radiography*

### Bone classification related to implant dentistry

*Lekholm and zarb (12) alveolar bone grading scale*

According to this system alveolar bone has been divided into 4 classes:

1. Almost the entire jawbone is composed of homogenous compact bone.
2. Thick layer of compact bone surrounds a core of dense trabecular bone.
3. A thin layer of compact bone surrounds a core of dense trabecular bone of favourable strength.
4. A thin layer of compact bone surrounds a core of low density trabecular bone.

The quality of the implant site in terms of relative proportion and density of cortical and medullary bone had frequently been assessed using a grading scheme.

*Lindh et al (13) method of classification of alveolar bone*

It is a recent method of classification based on periapical radiographs that grades the medullary bone as A) Dense B) Sparse and C) Alternating dense and sparse trabeculation.

*Misch Bone Density Classification (14)*

D1 - Dense cortical bone, D2 - Thick dense to porous cortical bone on crest and coarse trabecular bone within, D3 - Thin porous cortical bone on crest and fine trabecular bone within, D4 - Fine trabecular bone and D5 - Immature, non-mineralized bone.

### Radiographic bone density

Bone density may be more precisely determined by tomographic radiographs, especially computerized tomograms. Computerized tomography (CT) produces axial images of the patient's anatomy, perpendicular to the axis of the body. The very soft bone observed after some bone grafts may be 100 to 300 units.

The bone density may be different near the crest compared with the apical region where the implant placement is planned. The most critical region of bone density is the crestal 7 to 10 mm of bone. Therefore when the bone density varies from the most crestal to apical region around the

## Dental implant imaging

implant, the crestal 7 to 10 mm determines the treatment plan protocol (8).

### Imaging modalities

#### *Intraoral periapical radiographs*

Intraoral periapical radiographs, are made using paralleling technique (9). Periapical radiography used to rule out the presence of pathosis, location of anatomic structures in relation to implant site (1). It also determines vertical height, architecture and bone quality [density, amount of cortical bone and amount of trabecular bone] (11).

*Digital Radiography:* Direct digital intraoral imaging is an emerging and alternative technique to film radiography. It allows rapid acquisition of intraoral images and their enhancement, their storage, retrieval, and transmission to remote sites. The future utility of digital imaging may rest with the operator's ability to manipulate image density and contrast and to measure bone density at specific sites (1).

*Intraoral imaging using electronic or CCD imaging techniques:* With charge coupled devices (CCDs) presurgical implant assessment of single sites becomes precise. CCDs allow accurate measurement of implant sites preoperatively and provide more information about osseointegration postoperatively than with film. The use of wire grids helps in site selection and bone height determination. Multiple images of a site allow two and three dimensional reconstruction of the proposed site and allow viewing the information on a video monitor prior to placement (15).

#### *Occlusal Radiographs*

Occlusal radiographs are used for the edentulous mandible/maxilla to obtain information regarding bucco-lingual width and contour (1).

*Applications:* Individual implant sites and mapping for multidirectional tomography.

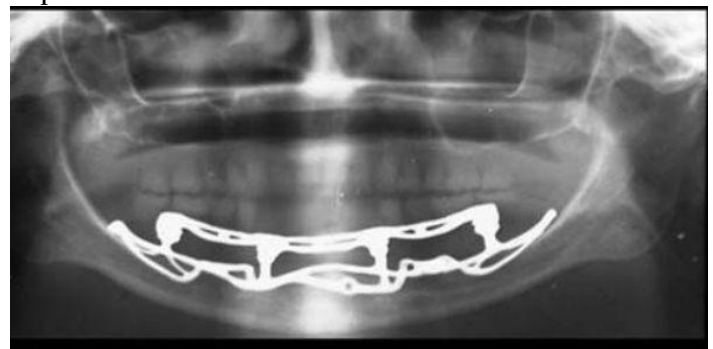
#### *Cephalometric radiography*

Cephalometric radiographs with lateral, posteroanterior and oblique views of the jaws will provide pertinent information like angulation, thickness and vertical bone height in the midline, inter-jaw skeletal relationships and the soft tissue profile (9). Together with regional periapical radiographs, quantitative spatial information is available to demonstrate the geometry of implant site and the spatial relationship between implant site and critical structures such as the floor of nasal cavity, the anterior recess of maxillary sinus and the nasal palatine canal (8).

#### *Panoramic radiography (Figure-1)*

Panoramic radiographs are used for the longitudinal assessment of the success of the implant. Panoramic images provide a broader visualization of the jaws and adjoining anatomic structures. These are widely available and can be used as screening radiograph. They are also used to assess the crestal alveolar bone and cortical boundaries of the mandibular canal, maxillary sinus and nasal fossa (11).

**Figure 1:** Panoramic radiograph demonstrating a mandibular subperiosteal implant.



*Zonography:* Recently, a modification of the panoramic x-ray machine has been developed that has the capability of making a cross-sectional image of the jaws. These devices employ limited angle linear tomography (zonography) and a means for

## Dental implant imaging

positioning the patient. This technique enables the appreciation of spatial relationship between the critical structures and implant site and quantification of geometry of implant site. It has limited usefulness, especially in the anterior regions. The tomographic layers are relatively thick and have adjacent structures that are blurred and superimposed on the image, limiting the usefulness of this technique for individual sites, especially in the anterior regions where the geometry of alveolous changes relatively rapidly. This technique is not useful for determining the differences in most bone densities or identifying disease at implant site (8).

### **Cross Sectional Imaging**

Cross sectional imaging include

- Conventional tomography.
- Computed tomography (CT).
- Magnetic resonance imaging (MRI).

#### Conventional tomography: (Figure-2)

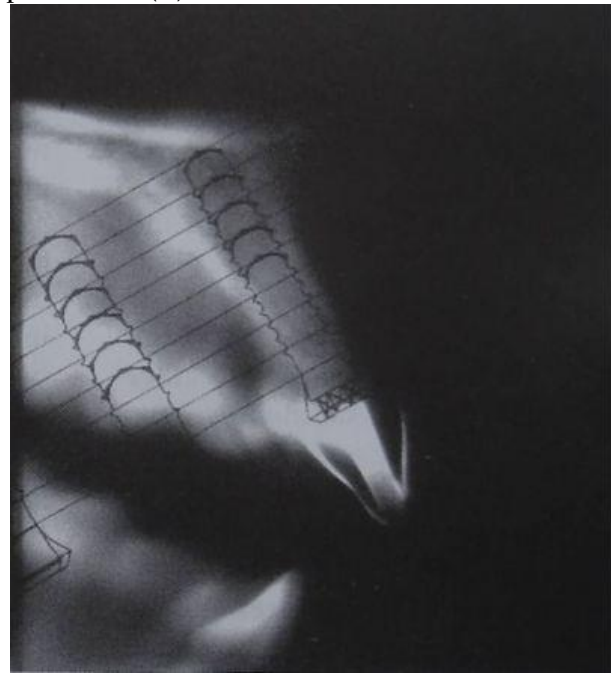
Conventional film- based tomography is designed to obtain clear images of structures lying within a plane of interest (2). It used for accurate assessment of alveolar bone height, width and inclination. It can assess both the quality and quantity of the bone. It gives information regarding the spatial relationship of vital structures (2).

#### Computed tomography (CT): (Figure-3)

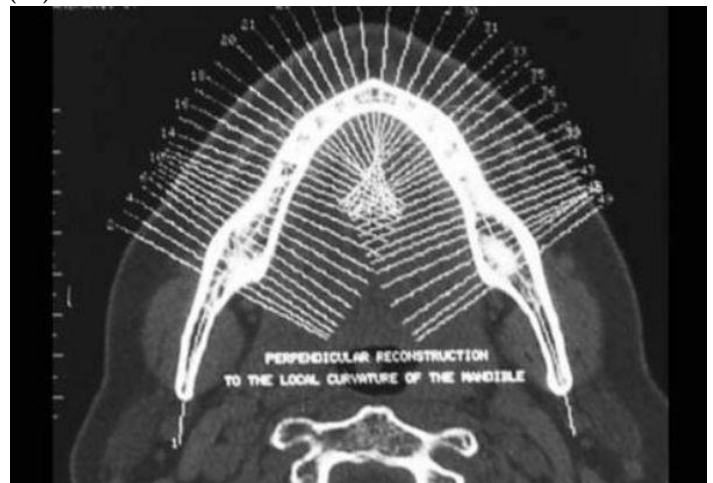
CT was first applied successfully in implantology in the 1980s (2). In CT implant imaging, multiple thin axial slices are obtained through jaws and then the data are reformatted with special software packages to produce cross-sectional and panoramic views. Computer software programs are available to analyze the reformatted images and aid in planning implant placement with electronically simulated fixtures, measure the distance from the alveolar crest to vital structures (17). Computer assisted tomography has become popular in implant and temporomandibular joint imaging with the advent of precise positioning techniques controlled by computer work stations. The

complex motion tomographic machines incorporates most of the complex motions of tomography like circular, trispiral, elliptical, hypocycloidal (18).

**Figure 2:** Conventional tomogram showing clear plastic overlay used to visualize and determine desired length of implant placement (11).



**Figure 3:** Axial CT view of the mandible showing the potential cross-sectional slices that can be reformatting by Dentascan (18).



## Dental implant imaging

### *Cone Beam Computed Tomography*

Cone beam CT is a relatively newer modality, specifically designed for maxillofacial imaging introduced in the late 1990s. It is characterized by true volumetric data acquisition obtained simultaneously during one rotation of the x-ray source. It produces a 3-D image volume that can be reformatted using software for customized visualization of the anatomy. It gives all the information of CT at  $1/8^{\text{th}}$  the radiation dose and at a lower cost (17).

### *Tuned Aperture Computed Tomography (TACT)*

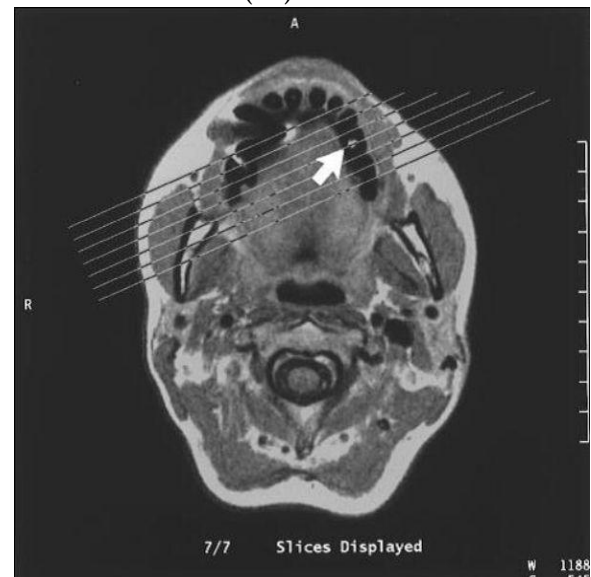TACT is a new and promising method for dentoalveolar imaging based on optical aperture theory. This technique uses information collected by passing a radiograph beam through an object from several different angles. A prototype developed for dental applications has a cluster of small radiograph tubes that can be fired in close sequence. The relationship of the source and the object can be used to determine projection geometry after the exposure is complete. TACT can map the incrementally collected data into a single 3-dimensional matrix. It can isolate the images of desired structures limited to certain depths. It has the ability to accommodate patient's motion between exposures. It has considerable flexibility to adjust contrast and resolution (19).

### Magnetic resonance imaging (MRI): (Figure 4)

Magnetic resonance imaging (MRI) is based on the phenomenon of nuclear magnetic resonance (NMRI). First described in 1946, its application in implantology is however of recent origin (2). MRI with a 0.2 Tesla low field scanner, has shown definite potential as a future replacement for CT imaging with the obvious advantages that it delivers no ionizing radiation (20). MRI is used in implant imaging as a secondary imaging technique when primary imaging techniques fail. MRI visualizes the fat in trabecular bone and differentiates the inferior alveolar canal

and neurovascular bundle from the adjacent trabecular bone (21). Oriented MRI imaging of the posterior mandible is dimensionally quantitative and enables spatial differentiation between critical structures and the proposed implant site. MRI is not useful in characterizing bone mineralization or a high-yield technique for identifying bone or dental disease (8).

**Figure 4:** A transaxial image showing the marker indicating the potential implant site (arrow). The lines show the planned position of a set of images at right-angles to the maxilla at the site (20)



*Advantages:* MRI can sharply delineate soft and hard tissues, differentiate between cortical and cancellous bones, zero radiation dose, flexibility of plane acquisition, gives good soft tissue details and less artifacts.

*Disadvantages:* Expensive, no special software is available for specific use in implantology, an expert radiologist is required to interpret and its application in implantology is still in its experimental phase (2).

## Diagnostic imaging for preoperative planning

Periapical radiographs may be supplemental when high detailed images are

## Dental implant imaging

indicated. To assess the suitability of an implant site i.e. to assess the mesial/distal view, a panoramic radiograph is appropriate because it provides the view of both jaws. Imaging information from panoramic, cephalometric and intra-oral films alone is inadequate to evaluate the bony architecture of any implant site completely.

The AAOMR recommends that evaluation of any potential implant site include cross sectional imaging orthogonal to the site of interest. This information is best acquired with tomography, either conventional or CT. Conventional film tomographic views are most useful when complex motions are used such as spiral or hypocycloidal patterns, instead of linear movement. CT is most appropriate for patients who are being considered for many implants [8-10 or more] (9).

### Surgical and interventional imaging

Surgical and interventional imaging involves imaging the patient during and immediately after surgery and during the placement of the prosthesis. The purpose of surgical imaging is to evaluate the depth of implant placement, the position and orientation of implants/osteotomies, and to evaluate donor or graft sites. Because most implant surgeries are performed in the doctor's office rather than a hospital, the modalities are usually limited to periapical and panoramic radiography (22).

#### *Digital periapical radiography*

Digital periapical image receptors enable virtually instantaneous image acquisition, produce image quality similar to that of dental film, and enable the surgical procedure to proceed without undue delay. Image enhancement and the digital measuring techniques, can help the surgeon in establishing the optimum depth and orientation of the implants (23). The image can be manipulated to change the density

and contrast and to measure the bone density at specific sites (1).

#### *Panoramic Radiography*

For extensive implant procedures that may involve the entire jaw, both jaws, large donor graft sites, or sinus graft augmentation, panoramic radiography will provide a more global view of the patient's anatomy. Patient must generally leave the surgical site and stand or sit still for the panoramic procedure, less resolution and shows magnification and distortion (8).

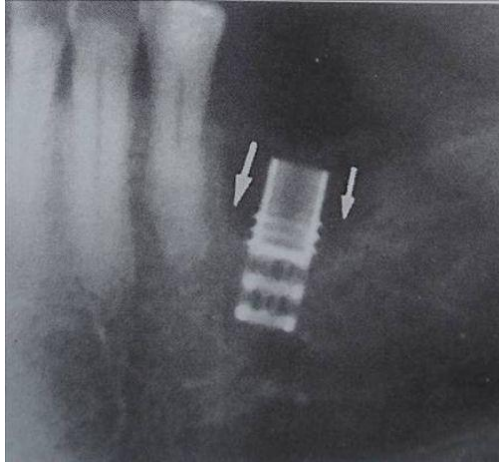
### Postsurgical assessment

The purpose of post-prosthetic implant imaging is to evaluate the status and prognosis of the dental implant. The bone adjacent to the dental implant should be evaluated for successful integration, fibrous tissue interfaces, inflammation, or infection, loss of crestal bone (**Figure-5**) adjacent to the dental implant, excessive functional loading, or para functional loading. Loss of cylindrical bone volume adjacent to the implant surface may indicate excessive axial or shear loading, bone damage during implant placement, integration failure with an epithelial bone implant interface, inflammation, and/or infection (8).

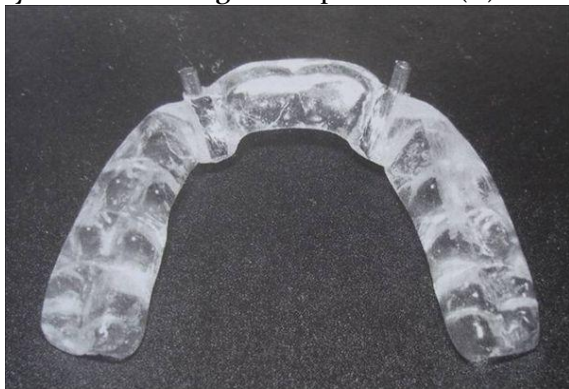
Marginal bone loss of approximately 1.2 mm in the first year and 0.1mm in subsequent years is generally considered acceptable. Conventional intraoral and panoramic radiography are most widely used for post surgical assessment and in most cases, are adequate for this task. The short- and long-term evaluation of crestal bone loss around implants is best evaluated with Bite-wing radiographs. In these images, the superior one third of the implant is the region of interest (23). Cross-sectional imaging is usually not required for routine post-surgical evaluation of implants. However, it may be of benefit in certain cases to evaluate potential complications (17).

## Dental implant imaging

**Figure 5:** Periapical radiograph showing moderate bone loss (saucerization type) cervical region (11).



**Figure 6:** Processed stent with metal cylinders marking the implant sites (11).



### Diagnostic templates or imaging stents

The value of imaging may be enhanced with the use of an imaging stent. The intended implant sites are identified by markers made of radiopaque spheres or rods (metal, composite resin, and gutta-percha) retained within an acrylic stent which the patient wears during imaging procedure (figure-6). Diagnostic dentures coated with barium paste may be used during imaging. Only nonmetallic radiopaque markers are (gutta-percha, composite resin) used in CT imaging because metal markers produce image artifacts. Stents facilitate the

application of bone measurements from the radiograph to the clinical scenario. Stents also may be designed to evaluate the path of insertion and axial inclination of the anticipated implant and the emergence profile of the implant. Most imaging stents can be converted to surgical guides for use in the surgical phase of implant treatment to orient the insertion angle of the guide bur and the angle of the implant. For optimal visualization the width of the markers should be less than the thickness of conventional tomographic image layer (11).

### Interactive diagnostic software

Several different interactive software packages have been developed to allow presurgical simulation of implant orientation and placement on a computer screen. The software is available for both conventional tomography and reformatted computed tomography. The softwares available for conventional tomography are SURGPlan [Imaging Sciences International, Hatfield, Penn.] (11) and for reformatted computed tomography are DentaScan [General Electric, Milwaukee, Wis.] and its advanced version DentaScan Plus, (18) 3-D Dental [Columbia Scientific Inc., Columbia, Md.], ToothPix [Cemax Inc., Fremont, Calif.] and SIM-Plant [Materialise Medical, Glen Burnie, Md.]. These programs permit analysis of potential implant sites for bone quantity, quality and morphology as well as simulating the surgical placement of the implant in real time (11).

### Dosimetry

The effective doses and risk of implant imaging is presented in table 2

**Cost:** The issue of implant imaging costs arises in the choice between conventional tomography and CT. the average cost of conventional tomography is \$ 125 (75-250) for a single rate and \$286 (220-350) for 6 implant

## Dental implant imaging

**Table-2:** Effective doses and risk from implant imaging [9].

Author	Technique	Effective dose ( $\mu\text{Sv}$ )		Fatal cancer risk/ $10^6$ exams		Stochastic effects / $10^6$ exams	
White	Full mouth survey	84.0		2.5			
White	Panoramic	6.7		0.21			
Frederiksen et al		Maxilla	Mandible	Maxilla	Mandible	Maxilla	Mandible
	Conventional tomography (single site)	25-56	25-56	-	-	1.9- 4.1	1.9- 4.1
Frederiksen et al	Computed tomography	104	761	-	-	8	56
Dula et al	Conventional tomography (single site)	120	80	1.6-9.5	1.5- 6.3		
Dula et al	Entire arch 6 sites	390	390	4.8-31.4	4.8- 30.4		
Dula et al	Computed tomography	580	480	12.1-46.2	11.2-36.4		
Scaf et al	Conventional tomography (single site)	26-36	187-189			2	14
Scaf et al	Computed tomography	1202	3324			88	242

sites in a single arch, versus \$ 679 (450-1000) for a single arch CT scan (26).

### Selection of imaging modality

The applications, advantages, disadvantages and radiation doses of various imaging modalities are presented in table 3

### Summary and conclusions

Many radiographic projections are available for implant imaging. Intraoral, panoramic and cephalometric radiography may be used best during initial phase of patient evaluation. Once the decision for implant placement has been made, the proposed site must be further evaluated using conventional tomography or CT. Film tomography is the most cost effective technique for evaluating single sites or several sites within the same quadrant multiple sites several quadrants in dentate patients or multiple sites in edentulous patents may be more effectively studied by CT. MRI is not commonly used for implant imaging because bony detail cannot be

readily appreciated. The cost of the procedure and radiation dose should also be weighed to the benefit of anticipated information.

To conclude, the imaging modalities that exist today can enhance the success and satisfaction with implant placement. Selection of projection should be made with consideration to the type and number of implants, location and surrounding anatomy. As in the case of all imaging, appropriate selection criteria must be applied individually to each patient.

## Dental implant imaging

**Table-3:** Selection of Imaging Modality [11]

Imaging modality	Applications	Cross-sectional information	Advantages	Disadvantages	Radiation dose
Periapical Radiography	S,M,E,A	No	<ul style="list-style-type: none"> <li>• Readily available</li> <li>• High resolution</li> <li>• Low cost</li> <li>• minimal distortion</li> </ul>	<ul style="list-style-type: none"> <li>• limited imaging area</li> <li>• no facial-lingual dimension</li> <li>• limited reproducibility</li> <li>• image elongation or foreshortening</li> </ul>	Low
Occlusal radiography	S,M,A	No	<ul style="list-style-type: none"> <li>• Readily available</li> <li>• High image definition</li> <li>• Gross Facial-lingual dimension</li> <li>• Relatively large imaging area</li> <li>• Low cost</li> </ul>	<ul style="list-style-type: none"> <li>• No detailed facial-lingual dimension</li> <li>• Limited reproducibility</li> <li>• Not as applicable for maxilla</li> <li>• Image superimposition</li> </ul>	Low
Panoramic radiography	S,M,E,A	No	<ul style="list-style-type: none"> <li>• Readily available</li> <li>• Large imaging area</li> <li>• Minimal cost</li> </ul>	<ul style="list-style-type: none"> <li>• No detailed facial-lingual dimension</li> <li>• Image distortion</li> <li>• Technique errors are common</li> <li>• Inconsistent magnification</li> <li>• Geometric distortion</li> </ul>	Low
Conventional tomography	S,M,E,A	Yes	<ul style="list-style-type: none"> <li>• Minimal superimposition</li> <li>• Facial-lingual dimension</li> <li>• Uniform magnification</li> <li>• Accurate measurements</li> <li>• Moderate cost</li> <li>• Simulates placement with software</li> </ul>	<ul style="list-style-type: none"> <li>• Less image definition than plain films</li> <li>• somewhat limited availability</li> <li>• special training for interpretation</li> <li>• sensitive to technique errors</li> </ul>	Moderately low, depends on sites
Reformatted Computed tomography	M,E,A	Yes	<ul style="list-style-type: none"> <li>• allows evaluation of all possible sites</li> <li>• no superimposition</li> <li>• uniform magnification</li> <li>• Accurate measurements</li> <li>• Simulates placement with software</li> </ul>	<ul style="list-style-type: none"> <li>• Limited availability</li> <li>• sensitive to technique errors</li> <li>• metallic image artifacts</li> <li>• special training for interpretation</li> <li>• High cost</li> </ul>	High

*S- single implant, M- multiple implants (2-5), E- edentulous (6+), A- augmentation*

## Dental implant imaging

### References

1. Frederickson NL. Diagnostic imaging in dental implantology. *Oral Surg Oral Med Oral Pathol Oral Radiol Endod.* 1995;80:540-1.
2. Bhat S, Shetty S, Shenoy KK. Imaging in Implantology. *J Indian Prosthodontic Society.* 2005;5:10-4.
3. Lekholm U. The surgical site. In: Lindhe J, Karring T, Lang NP, editors. *Clinical periodontology and implant dentistry.* Copenhagen: Munksgaard, 1997.
4. Palmer RM, Smith BJ, Howe LC, Palmer PJ. Treatment planning: general considerations. In: Palmer RM, Smith BJ, Howe LC, Palmer PJ, editors. *Implants in clinical dentistry.* London: Martin Dunitz Ltd, 2002.
5. Bahat O. Treatment planning and placement of implants in the posterior maxillae: report of 732 consecutive Nobelpharma implants. *Int J Oral Maxillofac Implants.* 1993; 8:151-61.
6. Bain CA, Moy PK. The association between the failure of dental implants and cigarette smoking. *Int J Oral Maxillofac Implants.* 1993; 8:609-15.
7. Goodacre CJ, Kan JY, Rungcharassaeng K. Clinical complications of osseointegrated implants. *J Prosthet Dent.* 1999; 81:537-52.
8. Kircos LT, Misch CE. Diagnostic Imaging and Techniques. In Misch CE editor. *Contemporary Implant Dentistry, 2<sup>nd</sup> edition,* St. Louis , Bosto, London, Philadelphia; 1999.
9. Tyndall AA, Brooks SL. Selection criteria for dental implant site imaging: a position paper of the American Academy of Oral and Maxillofacial radiology. *Oral Surg Oral Med Oral Pathol Oral Radiol Endod.* 2000; 89:630 - 37.
10. Pharoah MJ. Imaging techniques and their clinical significance. *Int J Prosthodontics.*1993; 6: 176 - 79.
11. Shetty V, Benson BW. Orofacial Implants. In White SC, Pharoah MJ, editors. *Oral Radiology: principles and interpretation.* 5<sup>th</sup> edition, St. Louis: Mosby, Inc; 2004. pp 677-92.
12. Lekholm U, Zarb GA. Patient selection and preparation. In Branemark PI, Zarb GA, Albrektsson T, editors. *Tissue integrated prosthesis. Osseointegration in clinical dentistry.* Chicago: Quintessence, 1985.
13. Lindh C, Petersson A, Rohlin M. Assessment of the trabecular pattern before endosseous implant treatment. Diagnostic outcome of Periapical radiography in the mandible. *Oral Surg Oral Med Oral Pathol Oral Radiol Endod.* 1996; 82:335 - 43.
14. Misch CE. Density of bone: effect on treatment plans, surgical approach, healing and progressive bone loading. *Int J Oral Implant* 1990; 6(2):23-31.
15. Miles D.A, Van Dis M.L. Implant Radiology. *Dental Clinics of North America* 1993; 37 oct (4):645-68.
16. Wyatt Cris CL, Pharoah MJ. Imaging Techniques and Image Interpretation for Dental Implant Treatment. *Int J Prosthodont.* 1998; 11(5): 442 -52.
17. Mallya S.M., Potluri A. Diagnostic imaging for implants. *JIAOMR* 2004;16(3):174-79.
18. Mupparapu M, Singer SR. Implant imaging for the dentist. *J Can Dent Assoc.* 2004; 7 (1): 32 - 32g.
19. Reiskin AB. Implant Imaging. *Dental Clinics of North America* 1998; 42(1): 47-56.
20. Gray CF, Red path TW, Smith FW. Low field Magnetic Resonance imaging for Implant Dentistry. *Dentomaxillofacial Radiol.* 1998; 27:225 - 29.
21. Zabalegui J, Gil JA, Zabalegui B. Magnetic resonance imaging as an adjunctive diagnostic aid in patient selection for endosseous implants: preliminary study. *Int J Oral Maxillofac Impl.*1991; 5: 283 - 88.

## Dental implant imaging

22. Hendrick RT, Dove SB, Peters DD. Radiographic determination of canal length: direct digital radiography versus conventional radiography. *J Endodont.* 1994; 20 (7): 320 -26.
23. Jeffcoat MK: Application of digital radiography to implantology. *J Dent Symp.* 1993; 1:30-33.
24. Grondahl K, Ekestubbe A, Grondahl HG. Technical considerations for intraoral radiography in postoperative examination. *Nobel Biocare Global Forum.* 1996; 10 (3):10 - 11.
25. Meffert RM. Treatment of the ailing, failing implant. *Calif Den Assoc J.* 1992; 6:42 - 45.
26. Scaf G Et al. Dosimetry and Cost of imaging osseointegrated implants with film-based and computed tomography. *Oral Surg Oral Med Oral pathol Oral Radiol Endod.* 1997; 123-27.